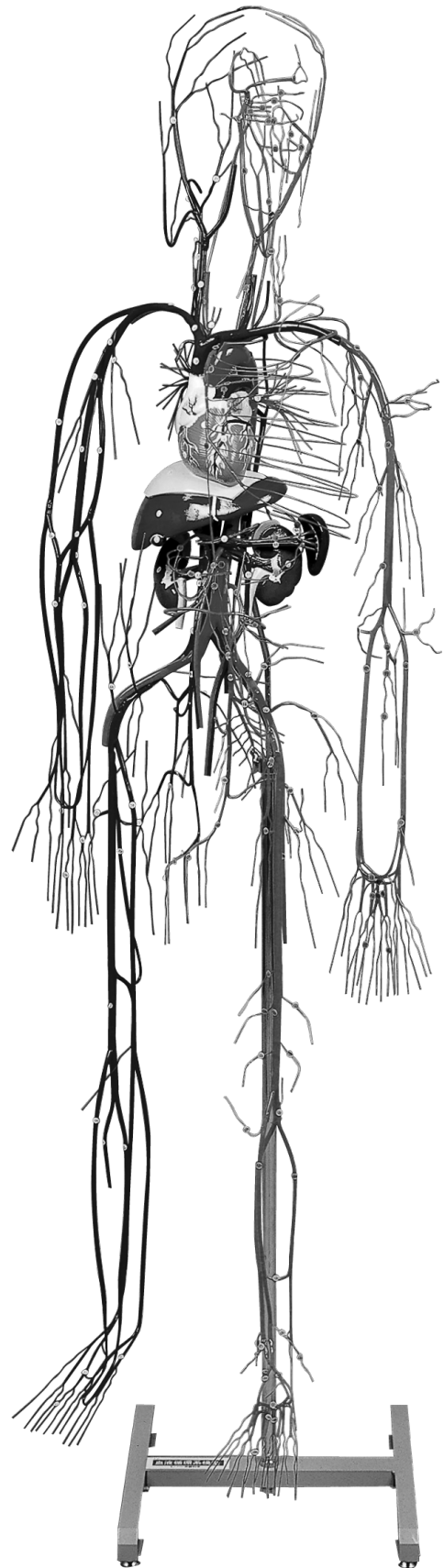


**NO. A61**

KEY CHART FOR MODEL

# Vascular System Model

血液循環系模型



□ KYOTO KAGAKU co.,LTD

MADE IN JAPAN

**KEY CHART FOR MODEL  
NO. A61  
Vascular System Model**

**Yellow Labels**

**A. Heart**

1. Right atrium
2. Right auricle
3. Right ventricle
4. Left atrium
5. Left auricle
6. Left ventricle

**B. Diaphragm**

**C. Liver**

**D. Gall bladder**

**E. Spleen**

**F. Right kidney**

**G. Left kidney**

**A. Cor**

1. Atrium dextrum
2. Auricula dextra
3. Ventriculus dexter
4. Atrium sinistrum
5. Auricula sinistra
6. Ventriculus sinister

**B. Diaphragma**

**C. Hepar**

**D. Vesica fellea**

**E. Lien**

**F. Ren dexter**

**G. Ren sinister**

**A. 心臟**

1. 右心房
2. 右心耳
3. 右心室
4. 左心房
5. 左心耳
6. 左心室

**B. 橫隔膜**

**C. 肝臟**

**D. 膽囊**

**E. 脾臟**

**F. 右腎**

**G. 左腎**

**Blue Labels**

**Arteries**

1. Pulmonary trunk
2. Right pulmonary artery
3. Left pulmonary artery
4. Ligamentum arteriosum
5. Ascending aorta
6. Aortic arch
7. Descending aorta
8. Right coronary artery
9. Left coronary artery
10. Brachiocephalic artery
11. Common carotid artery
12. External carotid artery
13. Superior thyroid artery
14. Ascending pharyngeal artery
15. Lingual artery
16. Facial artery
17. Occipital artery
18. Posterior auricular artery
19. Superficial temporal artery
20. Maxillary artery
21. Inferior alveolar (dental) artery
22. Middle meningeal artery

**Arteriae**

1. Truncus pulmonalis
2. A. pulmonalis dextra
3. A. pulmonalis sinistra
4. Lig. arteriosum
5. Aorta ascendens
6. Arcus aortae
7. Aorta descendens
8. A. coronaria dextra
9. A. coronaria sinistra
10. Truncus brachiocephalicus
11. A. carotis communis
12. A. carotis externa
13. A. thyroidea superior
14. A. pharyngea ascendens
15. A. lingualis
16. A. facialis
17. A. occipitalis
18. A. auricularis posterior
19. A. temporalis superficialis
20. A. maxillaris
21. A. alveolaris inferior
22. A. meningea media

**動脈**

1. 肺動脈幹
2. 右肺動脈
3. 左肺動脈
4. 動脈管索
5. 上行大動脈
6. 大動脈弓
7. 下行大動脈
8. 右冠状動脈
9. 左冠状動脈
10. 腕頭動脈
11. 總頸動脈
12. 外頸動脈
13. 上甲状腺動脈
14. 上行咽頭動脈
15. 舌動脈
16. 顏面動脈
17. 後頭動脈
18. 後耳介動脈
19. 淺側頭動脈
20. 顎動脈
21. 下齒槽動脈
22. 中硬膜動脈

23. Posterior superior alveolar (dental) artery	23. A. alveolaris superior posterior	23. 後上齒槽動脈
24. Infraorbital artery	24. A. infraorbitalis	24. 眼窩下動脈
25. Anterior superior alveolar arteries	25. Aa. alveolares superiores anteriores	25. 前上齒槽動脈
26. Internal carotid artery	26. A. carotis interna	26. 內頸動脈
27. Ophthalmic artery	27. A. ophthalmica	27. 眼動脈
28. Anterior cerebral artery	28. A. cerebri anterior	28. 前大腦動脈
29. Middle cerebral artery	29. A. cerebri media	29. 中大腦動脈
30. Vertebral artery	30. A. vertebralis	30. 椎骨動脈
31. Posterior inferior cerebellar artery	31. A. cerebelli inferior posterior	31. 後下小腦動脈
32. Basilar artery	32. A. basilaris	32. 腦底動脈
33. Anterior inferior cerebellar artery	33. A. cerebelli inferior anterior	33. 前下小腦動脈
34. Internal auditory artery	34. A. labyrinthi	34. 迷路動脈
35. Superior cerebellar artery	35. A. cerebelli superior	35. 上小腦動脈
36. Posterior cerebral artery	36. A. cerebri posterior	36. 後大腦動脈
37. Subclavian artery	37. A. subclavia	37. 鎖骨下動脈
38. Internal thoracic (mammary) artery	38. A. thoracica interna	38. 內胸動脈
39. Superior epigastric artery	39. A. epigastrica superior	39. 上腹壁動脈
40. Thyrocervical trunk	40. Truncus thyrocervicalis	40. 甲狀頸動脈
41. Costocervical trunk	41. Truncus costocervicalis	41. 助頸動脈
42. Superior intercostal artery	42. A. intercostalis suprema	42. 最上助間動脈
43. Deep cervical artery	43. A. cervicalis profunda	43. 深頸動脈
44. Transverse cervical artery	44. A. transversa colli	44. 頸橫動脈
45. Axillary artery	45. A. axillaris	45. 腋窩動脈
46. Superior thoracic artery	46. A. thoracica suprema	46. 最上胸動脈
47. Thoracoacromial artery	47. A. thoracoacromialis	47. 胸肩峰動脈
48. Lateral thoracic artery	48. A. thoracica lateralis	48. 外側胸動脈
49. Subscapular artery	49. A. subscapularis	49. 肩甲下動脈
50. Thoracodorsal artery	50. A. thoracodorsalis	50. 胸背動脈
51. Scapular circumflex artery	51. A. circumflexa scapulae	51. 肩甲回旋動脈
52. Anterior humeral circumflex artery	52. A. circumflexa humeri anterior	52. 前上腕回旋動脈
53. Posterior humeral circumflex artery	53. A. circumflexa humeri posterior	53. 後上腕回旋動脈
54. Brachial artery	54. A. brachialis	54. 上腕動脈
55. Profunda brachii artery	55. A. profunda brachii	55. 上腕深動脈
56. Middle collateral artery	56. A. collateralis media	56. 中側副動脈
57. Radial collateral artery	57. A. collateralis radialis	57. 橈側側副動脈
58. Superior ulnar collateral artery	58. A. collateralis ulnaris superior	58. 上尺側側副動脈
59. Inferior ulnar collateral artery	59. A. collateralis ulnaris inferior	59. 下尺側側副動脈
60. Radial artery	60. A. radialis	60. 橈骨動脈
61. Radial recurrent artery	61. T. recurrens radialis	61. 橈側反回動脈
62. Superficial palmar (volar) branch	62. Ramus palmaris (volaris) superficialis	62. 淺掌枝
63. Dorsal metacarpal arteries	63. Aa. metacarpeae dorsales	63. 背側中手動脈
64. Dorsal digital arteries	64. Aa. digitales dorsales	64. 背側指動脈

65. Deep palmar (volar) arch	65. Arcus palmaris (volaris) profundus	65. 深掌動脈弓
66. Palmar (volar) metacarpal arteries	66. Aa. metacarpeae palmares (volares)	66. 掌側中手動脈
67. Ulnar artery	67. A. ulnaris	67. 尺骨動脈
68. Ulnar recurrent artery	68. A. recurrens ulnaris	68. 尺側反回動脈
69. Common interosseous artery	69. A. interossea communis	69. 總骨間動脈
70. Dorsal interosseous artery	70. A. interossea dorsalis	70. 後骨間動脈
71. Palmar (volar) interosseous artery	71. A. interossea palmaris (volaris)	71. 前骨間動脈
72. Median artery	72. A. mediana	72. 正中動脈
73. Superficial palmar (volar) arch	73. Arcus palmaris (volaris) superficialis	73. 淺掌動脈弓
74. Common palmar (volar) digital arteries	74. Aa. digitales palmares (volares) communes	74. 總掌側指動脈
75. Proper palmar (volar) digital arteries	75. Aa. digitales palmares (volares) propriae	75. 固有掌側指動脈
76. Thoracic aorta	76. Aorta thoracica	76. 胸大動脈
77. Intercostal arteries	77. Aa. intercostales	77. 助間動脈
78. Abdominal aorta	78. Aorta abdominalis	78. 腹大動脈
79. Inferior phrenic artery	79. A. phrenica	79. 下橫隔動脈
80. Superior suprarenal artery	80. A. suprarenalis superior	80. 上副腎動脈
81. Lumbar arteries	81. Aa. lumbales	81. 腰動脈
82. Median sacral artery	82. A. sacralis mediana	82. 正中仙骨動脈
83. Celiac arter	83. Truncus coeliaca	83. 腹腔動脈
84. Left gastric artery	84. A. gastrica sinistra	84. 左胃動脈
85. Common hepatic artery	85. A. hepatica communis	85. 總肝動脈
86. Right gastric artery	86. A. gastrica dextra	86. 右胃動脈
87. Hepatic proper artery	87. A. hepatica propria	87. 固有肝動脈
88. Gastroduodenal artery	88. A. gastroduodenalis	88. 胃十二指腸動脈
89. Right gastroepiploic artery	89. A. gastroepiploica dextra	89. 右胃大網動脈
90. Lienal or splenic artery	90. A. lienalis	90. 脾動脈
91. Left gastroepiploic artery	91. A. gastroepiploica sinistra	91. 左胃大網動脈
92. Short gastric arteries	92. Aa. gastricae breves	92. 短胃動脈
93. Superior mesenteric artery	93. A. mesenterica superior	93. 上腸間膜動脈
94. Inferior mesenteric artery	94. A. mesenterica inferior	94. 上腸間膜動脈
95. Left colic artery	95. A. colica sinistra	95. 左結腸動脈
96. Superior rectal artery	96. A. rectalis superior	96. 上直腸動脈
97. Middle suprarenal artery	97. A. suprarenalis media	97. 中副腎動脈
98. Renal artery	98. A. renalis	98. 腎動脈
99. Inferior suprarenal artery	99. A. suprarenalis inferior	99. 下副腎動脈
100. Testicular (ovarian) artery	100. A. testicularis (ovarica)	100. 精巢 (卵巢) 動脈
101. Common iliac artery	101. A. iliaca communis	101. 總腸骨動脈
102. Internal iliac (hypogastric) artery	102. A. iliaca interna	102. 內腸骨動脈
103. Iliolumbar artery	103. A. iliolumbalis	103. 腸腰動脈
104. Lateral sacral arteries	104. Aa. sacrales laterales	104. 外側仙骨動脈
105. Obturator artery	105. A. obturatoria	105. 閉鎖動脈
106. Superior gluteal artery	106. A. glutea superior	106. 上殿動脈

107. Inferior gluteal artery	107. A. glutea inferior	107. 下殿動脈
108. Umbilical artery	108. A. umbilicalis	108. 臍動脈
109. Artery to ductus deferens or vas deferens	109. A. ductus deferentis	109. 精管動脈
110. Internal pudendal artery	110. A. pudenda interna	110. 內陰部動脈
111. Posterior scrotal arteries	111. Aa. scrotales posteriores	111. 外陰囊枝
112. Artery of penis	112. A. penis	112. 陰莖動脈
113. External iliac artery	113. A. iliaca externa	113. 外腸骨動脈
114. Inferior epigastric artery	114. A. epigastrica inferior	114. 下腹壁動脈
115. Femoral artery	115. A. femoralis	115. 大腿動脈
116. Superficial epigastric artery	116. A. epigastrica superficialis	116. 淺腹壁動脈
117. External pudendal arteries	117. Aa. pudendae externae	117. 外陰部動脈
118. Deep femoral artery	118. Aa. profunda femoris	118. 大腿深動脈
119. Medial femoral circumflex artery	119. A. circumflexa femoris medialis	119. 內側大腿回旋動脈
120. Lateral femoral circumflex artery	120. A. circumflexa femoris lateralis	120. 外側大腿回旋動脈
121. Descending genicular artery	121. A. genus descendens	121. 下行膝動脈
122. Popliteal artery	122. A. poplitea	122. 膝窩動脈
123. Lateral superior genicular artery	123. A. genus superior lateralis	123. 外側上膝動脈
124. Medial superior genicular artery	124. A. genus superior medialis	124. 內側上膝動脈
125. Lateral inferior genicular artery	125. A. genus inferior lateralis	125. 外側下膝動脈
126. Medial inferior genicular artery	126. A. genus inferior medialis	126. 內側下膝動脈
127. Anterior tibial artery	127. A. tibialis anterior	127. 前脛骨動脈
128. Posterior tibial recurrent artery	128. A. recurrens tibialis posterior	128. 後脛骨反回動脈
129. Anterior tibial recurrent artery	129. A. recurrens tibialis anterior	129. 前脛骨反回動脈
130. Anterior lateral or external malleolar artery	130. A. malleolaris anterior lateralis	130. 前外果動脈
131. Anterior medial or internal malleolar artery	131. A. malleolaris anterior medialis	131. 前內果動脈
132. Dorsalis pedis artery	132. A. dorsalis pedis	132. 足背動脈
133. Arcuate artery	133. A. arcuata	133. 弓狀動脈
134. Dorsal metatarsal arteries	134. Aa. metatarsae dorsales	134. 背側中足動脈
135. Dorsal digital arteries	135. Aa. digitales dorsales	135. 背側指動脈
136. Posterior tibial artery	136. A. tibialis posterior	136. 後脛骨動脈
137. Peroneal artery	137. A. peronea	137. 腓骨動脈
138. Communicating branch	138. Ramus communicans	138. 交通枝
139. Lateral posterior malleolar artery	139. A. malleolaris lateralis posterior	139. 外果枝
140. Lateral calcaneal branches	140. Rami calcaneares laterales	140. 外側踵骨枝
141. Posterior medial malleolar artery	141. A. malleolaris medialis posterior	141. 內果枝
142. Medial calcaneal branches	142. Rami calcaneares mediales	142. 內側踵骨枝
143. Medial plantar artery	143. A. plantaris medialis	143. 內側足底動脈
144. Lateral plantar artery	144. A. plantaris lateralis	144. 外側足底動脈
145. Plantar metatarsal arteries	145. Aa. metatarsae plantares	145. 底側中足動脈
146. Plantar arch	146. Arcus plantaris	146. 足底動脈弓
147. Digital branches	147. Aa. digitales plantares	147. 固有底側指動脈

## Pink Labels

### Veins

1. Right pulmonary veins
2. Left pulmonary veins
3. Coronary sinus
4. Great cardiac vein
5. Inferior vein of left ventricle
6. Middle cardiac vein
7. Superior vena cava
8. Right and left brachiocephalic veins
9. Inferior thyroid vein
10. Vertebral vein
11. Internal thoracic (mammary) vein
12. Superior intercostal vein
13. Internal jugular vein
14. Superior thyroid vein
15. Lingual vein
16. Facial vein
17. Anterior facial vein
18. Angular vein
19. Posterior facial vein
20. Superficial temporal veins
21. External jugular vein
22. Occipital vein
23. Subclavian vein
24. Axillary vein
25. Long thoracic vein
26. Subscapular vein
27. Brachial veins
28. Radial veins
29. Ulnar veins
30. Cephalic vein
31. Basilic vein
32. Median antebrachial vein
33. Median basilic vein
34. Median cephalic vein
35. Deep communicating vein
36. Dorsal venous network of hand
37. Dorsal metacarpal veins
38. Dorsal digital veins
39. Azygos vein
40. Hemiazygos vein
41. Accessory hemiazygos vein

### Venae

1. Vv. pulmonales dextrae
2. Vv. pulmonales sinistrae
3. Sinus coronarius
4. V. cordis magna
5. V. posterior ventriculi sinistri
6. V. cordis media
7. Vena cava superior
8. V. brachiocephalica dextra et sinistra
9. V. thyreoidea inferior
10. V. vertebralis
11. V. thoracica interna
12. V. intercostalis suprema
13. V. jugularis interna
14. V. thyreoidea superior
15. V. lingualis
16. V. facialis
17. V. facialis anterior
18. V. angularis
19. V. retromandibularis
20. Vv. temporales superficiales
21. V. jugularis externa
22. V. occipitalis
23. V. subclavia
24. V. axillaris
25. V. thoracalis lateralis
26. V. subscapularis
27. Vv. brachiales
28. Vv. radiales
29. Vv. ulnares
30. V. cephalica
31. V. basilica
32. V. mediana antebrachii
33. V. mediana basilica
34. V. mediana cephalica
35. V. mediana profunda
36. Rete venosum dorsale manus
37. Vv. metacarpicae dorsales
38. Vv. digitales dorsales propriae
39. V. azygos(thoracica longitudinalis dextra)
40. V. hemiazygos (thoracica longitudinalis sinistra)
41. V. hemiazygos accessoria  
(thoracica longitudinalis sinistra accessoria)

### 静脈

1. 右肺靜脈
2. 左肺靜脈
3. 冠狀靜脈洞
4. 大心靜脈
5. 左心室後靜脈
6. 中心靜脈
7. 上大靜脈
8. 腕頭靜脈 (左右)
9. 下甲狀腺靜脈
10. 椎骨靜脈
11. 內胸靜脈
12. 最上助間靜脈
13. 內頸靜脈
14. 上甲狀腺靜脈
15. 舌靜脈
16. 顏面靜脈
17. 前顏面靜脈
18. 眼角靜脈
19. 下顎後靜脈
20. 淺側頭靜脈
21. 外頸靜脈
22. 後頭靜脈
23. 鎖骨下靜脈
24. 腋窩靜脈
25. 外側胸靜脈
26. 助腋窩靜脈
27. 上腕靜脈
28. 橈骨靜脈
29. 尺骨靜脈
30. 橈側皮靜脈
31. 尺側皮靜脈
32. 前腕正中皮靜脈
33. 尺側正中皮靜脈
34. 橈側正中皮靜脈
35. 深正中靜脈
36. 手背靜脈網
37. 背側中手靜脈
38. 背側指靜脈
39. 奇靜脈
40. 半奇靜脈
41. 副半奇靜脈

42. Ascending lumbar vein	42. V. lumbalis ascendens	42. 上行腰靜脈
43. Inferior vena cava	43. Vena cava inferior	43. 下大靜脈
44. Lumbar veins	44. Vv. lumbales	44. 腰靜脈
45. Hepatic veins	45. Vv. hepaticae	45. 肝靜脈
46. Renal veins	46. Vv. renales	46. 腎靜脈
47. Testicular (ovarian) vein	47. V. testicularis(ovaris)	47. 精巢(卵巢)靜脈
48. Portal vein	48. V. portae	48. 門(靜)脈
49. Right and left gastric or coronary vein	49. V. gastrica dextra et sinistra (coronaria ventriculi)	49. 右胃及び左胃靜脈
50. Superior mesenteric vein	50. V. mesenterica superior	50. 上腸間膜靜脈
51. Right gastroepiploic vein	51. V. gastroepiploica dextra	51. 右胃大網靜脈
52. Inferior mesenteric vein	52. V. mesenterica inferior	52. 下腸間膜靜脈
53. Left colic vein	53. V. colica sinistra	53. 左結腸靜脈
54. Superior rectal vein	54. V. rectalis superior	54. 上直腸靜脈
55. Lienal or splenic vein	55. V. lienalis	55. 脾靜脈
56. Short gastric veins	56. Vv. gastricae breves	56. 短胃靜脈
57. Left gastroepiploic vein	57. V. gastroepiploica sinistra	57. 左胃大網靜脈
58. Common iliac vein	58. V. iliaca communis	58. 總腸骨靜脈
59. Internal iliac vein	59. V. iliaca interna	59. 內腸骨靜脈
60. Superior gluteal veins	60. Vv. gluteae superiores	60. 上殿靜脈
61. Inferior gluteal (sciatic) veins	61. Vv. gluteae inferiores	61. 下殿靜脈
62. Obturator veins	62. Vv. obturatoriae	62. 閉鎖靜脈
63. Lateral sacral veins	63. Vv. sacrales laterales	63. 外側仙骨靜脈
64. Iliolumbar vein	64. V. iliolumbalis	64. 腸腰靜脈
65. Dorsal vein of penis	65. V. dorsalis penis	65. 陰莖背靜脈
66. Scrotal veins	66. Vv. scrotales	66. 後陰囊靜脈
67. External iliac vein	67. V. iliaca externa	67. 外腸骨靜脈
68. Inferior epigastric vein	68. V. epigastrica inferior	68. 下腹壁靜脈
69. Superficial epigastric vein	69. V. epigastrica superficialis	69. 淺腹壁靜脈
70. Great saphenous vein	70. V. saphena magna	70. 大伏在靜脈
71. Medial femoral circumflex veins	71. Vv. circumflexae femoris mediales	71. 內側大腿回旋靜脈
72. Lateral femoral circumflex veins	72. Vv. circumflexae femoris laterales	72. 外側大腿回旋靜脈
73. Deep femoral vein	73. V. profunda femoris	73. 大腿深靜脈
74. Small saphenous vein	74. V. saphena parva	74. 小伏在靜脈
75. Femoropopliteal vein	75. V. femoropoplitea	75. 大腿膝窩靜脈
76. Peroneal veins	76. Vv. peroneae	76. 腓骨靜脈
77. Popliteal vein	77. V. poplitea	77. 膝窩靜脈
78. Posterior tibial veins	78. Vv. tibiales posteriores	78. 後頸骨靜脈
79. Anterior tibial veins	79. Vv. tibiales anteriores	79. 前頸骨靜脈
80. Common digital veins	80. Vv. digitales communes pedis	80. 背側指靜脈
81. Dorsal digital veins	81. Vv. digitales dorsales pedis	81. 背側足指靜脈
82. Dorsal venous network of foot (Plantar cutaneous venous network)	82. Rete venosum dorsale pedis	82. 足背靜脈網

 **KYOTO KAGAKU co.,LTD**

■ **Main Office and Factory**

15 KitaneKoya-cho Fushimi-ku Kyoto 612-8388, Japan  
Telephone : 81-75-605-2510 Facsimile : 81-75-605-2519

■ **LA Office ( for USA , CANADA and Mexico customers )**

3109 Lomita Boulevard, Torrance, CA 90505 ,USA  
Telephone : 1-310-325-8860 Facsimile : 1-310-325-8867

**URL ● <http://www.kyotokagaku.com>**  
**e-mail ● [rw-kyoto@kyotokagaku.co.jp](mailto:rw-kyoto@kyotokagaku.co.jp)**

 株式会社 **京都科学**

■ **本社・工場**

〒612-8388 京都市伏見区北寝小屋町15番地  
TEL : 075-605-2510 (直通) FAX : 075-605-2519

■ **東京支店**

〒113-0033 東京都文京区本郷三丁目26番6号  
NREG本郷三丁目ビル2階  
TEL : 03-3817-8071 (直通) FAX : 03-3817-8075