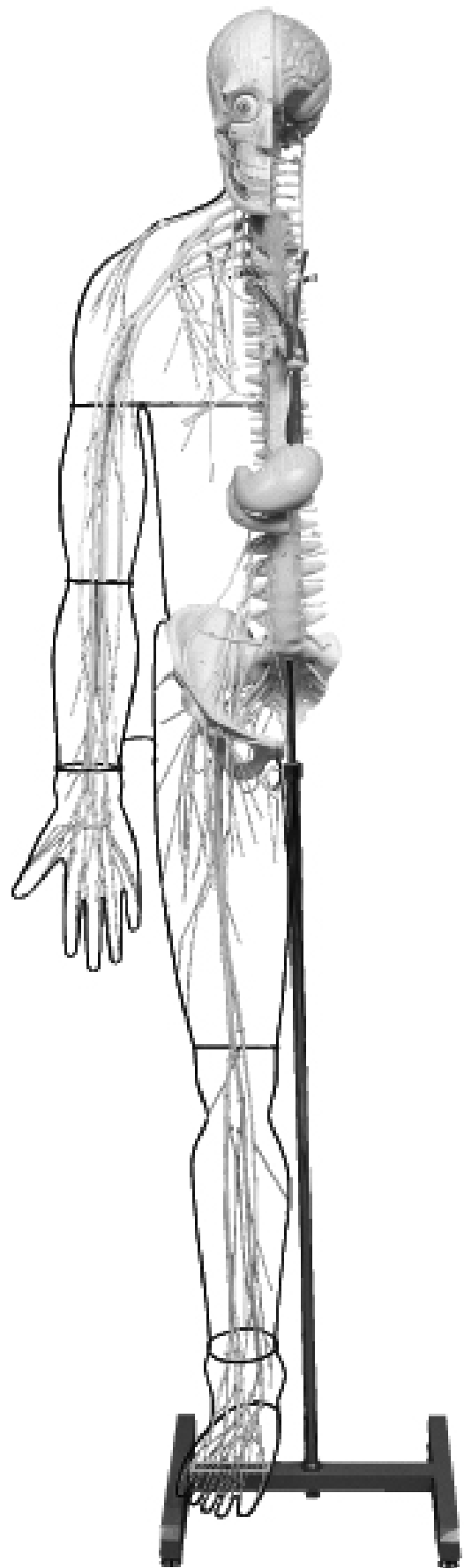


NO. A25

KEY CHART FOR MODEL

Full-figure Nervous System Model



 **KYOTO KAGAKU co.,LTD**

MADE IN JAPAN

**KEY CHART FOR MODEL
NO. A25
Full-figure Nervous System Model**

BRAIN	ENCEPHALON	腦
A. Frontal lobe of cerebrum	A. Lobus frontalis	A. 前頭葉
1. Marginal gyrus	1. Gyrus frontalis superior	1. 上前頭回
2. Middle frontal gyrus	2. Gyrus frontalis medius	2. 中前頭回
3. Inferior frontal gyrus	3. Gyrus frontalis inferior	3. 下前頭回
4. Precentral gyru	4. Gyrus precentralis	4. 中心前回
B. Parietal lobe of cerebrum	B. Lobus parietalis	B. 全頂葉
5. Postcentral gyrus	5. Gyrus postcentralis	5. 中心後回
6. Superior parietal lobule	6. Lobulus parietalis superior	6. 上頭頂小葉
7. Inferior parietal lobule	7. Lobulus parietalis inferior	7. 下頭頂小葉
C. Occipital lobe of cerebrum	C. Lobus occipitalis	C. 後頭葉
D. Temporal lobe	D. Lobus temporalis	D. 側頭葉
8. Superior temporal gyrus	8. Gyrus temporalis superior	8. 上側頭回
9. Middle temporal gyrus	9. Gyrus temporalis medius	9. 中側頭回
10. Inferior temporal gyrus	10. Gyrus temporalis inferior	10. 下側頭回
11. Lateral sulcus	11. Sulcus lateralis	11. 外側溝 (外側大腦裂)
E. Cerebellum	E. Cerebellum	E. 小腦
12. Biventer lobule	12. Lobulus biventer	12. 二腹小葉
13. Superior semilunar lobule	13. Lobulus semilunaris superior	13. 上半月小葉
14. Inferior lobulus semilunaris	14. Lobulus semilunaris inferior	14. 下半月小葉
15. Tonsil of cerebellum	15. Tonsilla cerebelli	15. 小腦扁桃
16. Floccule	16. Flocculus	16. 片葉
F. Pons	F. Pons	F. 橋
G. Medullary	G. Medulla oblongata	G. 延髓
SPINAL CORD	MEDULLA SPINALIS	脊髓
H. Cervical enlargement	H. Intumescentia cervicalis	H. 頸膨大
I. Lumbosacral enlargement	I. Intumescentia lumbalis	I. 腰膨大
J. Cauda equina	J. Cauda equina	J. 馬尾
PERIPHERAL NERVOUS SYSTEM	SYSTEMA NERVOSUM PERIPHERICUM	末梢神經系
CRANIAL NERVE	NERVI CRANIALES	腦神經
17. Olfactory nerves	17. Nn. olfactorii	17. 嗅神經
18. Optic nerve	18. N. opticus	18. 視神經
19. Oculomotor nerve	19. N. oculomotorius	19. 動眼神經
20. Trochlear nerve	20. N. trochlearis	20. 滑車神經
21. Trigeminal nerve	21. N. trigeminus	21. 三叉神經
22. Trigeminal ganglion	22. Ganglion trigeminale	22. 三叉神經節
23. Ophthalmic nerve	23. N. ophthalmicus	23. 眼神經

24. Supraorbital nerve (Medial branches)	24. N.supraorbitalis(Ramus medialis)	24. 眼窩上神経 (内側枝) (前頭神経の)
25. Supraorbital nerve (Lateral branches)	25. N.supraorbitalis(Ramus lateralis)	25. 眼窩上神経 (外側枝) (前頭神経の)
26. Supratrochlear nerve	26. N.supratrochlearis	26. 滑車上神経
27. Lacrimal nerve	27. N.lacrimalis	27. 涙腺神経
28. Maxillary nerve	28. N.maxillaris	28. 上顎神経
29. Anterior superior alveolar nerves	29. Rami alveolares superiores posteriores	29. 後上歯槽枝 (上歯槽神経の)
30. Infraorbital nerve	30. N.infraorbitalis	30. 眼窩下神経
31. Mandibular nerve	31. N.mandibularis	31. 下顎神経
32. Masseteric nerve	32. N.massetericus	32. 咬筋神経
33. Deep temporal nerves	33. Nn.temporales profundi	33. 深側頭神経
34. Buccal nerve	34. N.buccalis	34. 頬神経
35. Auriculotemporal nerve	35. N.auriculotemporalis	35. 耳介側頭神経
36. Nerve of external acoustic meatus	36. N.meatus acustici externi	36. 外耳道神経
37. Communicating branch of facial nerve	37. Rami communicantes cum n.faciali	37. 顔面神経との交通枝
38. Lingual nerve	38. N.lingualis	38. 舌神経
39. Inferior alveolar nerve	39. N.alveolaris inferior	39. 下歯槽神経
40. Mentalis nerve	40. N.mentalis	40. オトガイ神経
41. Otic ganglion	41. Ganglion oticum	41. 耳神経節
42. Abducent nerve	42. N.abducens	42. 外転神経
43. Facial nerve	43. N.facialis	43. 顔面神経
44. Parotid plexus	44. Plexus parotideus	44. 耳下腺神経叢
45. Marginal mandibular branch	45. Ramus marginalis mandibulae	45. 下顎縁枝
46. Vestibulocochlear nerve	46. N.vestibulocochlearis	46. 内耳神経
47. Glossopharyngeal nerve	47. N.glossopharyngeus	47. 舌咽神経
48. Vagus nerve	48. N.vagus	48. 迷走神経
49. Superior ganglion	49. Ganglion superius	49. 上神経節 (迷走神経の)
50. Inferior ganglion	50. Ganglion inferius	50. 下神経節 (")
51. Pharyngeal branches	51. Rami pharyngei	51. 咽頭枝 (")
52. Superior laryngeal nerve	52. N.laryngeus superior	52. 上喉頭神経 (")
53. Superior cervical cardiac branches	53. Rami cardiaci superiores	53. 上心臓枝 (")
54. Recurrent laryngeal nerve	54. N.laryngeus recurrens	54. 反回神経 (")
55. Oesophageal branches	55. Rami esophagei	55. 食道枝 (")
56. Tracheal branches	56. Rami tracheales	56. 気管枝 (")
57. Bronchial branches	57. Rami bronchiales	57. 気管支枝 (")
58. Esophageal plexus	58. Plexus esophageus	58. 食道神経叢 (")
59. Gastric plexuses	59. Plexus gastrici	59. 胃神経叢 (")
60. Accessory nerve	60. N.accessorius	60. 副神経
61. Hypoglossal nerve	61. N.hypoglossus	61. 舌下神経
62. Cervical ansa	62. Ansa cervicalis	62. 頸神経ワナ

SPINAL NERVES

- 63. Ventral root
- 64. Dorsal root
- 65. Spinal ganglion
- 66. Ventral branch
- 67. Posterior ramus

CERVICAL NERVES

- 68. Suboccipital nerve
- 69. Greater occipital nerve
- 70. Lesser occipital nerve
- 71. Supraclavicular nerves
- 72. Phrenic nerve

BRACHIAL PLEXUS

- 73. Dorsal nerve of scapula
- 74. Long thoracic nerve
- 75. Anterior thoracic nerve
- 76. Subclavian nerve
- 77. Suprascapular nerve
- 78. Subscapular nerves
- 79. Axillary nerve
- 80. Superior lateral brachial cutaneous nerve
- 81. Lateral cord
- 82. Medial cord
- 83. Posterior cord
- 84. Musculocutaneous nerve
- 85. Lateral antebrachial cutaneous nerve
- 86. Medial brachial cutaneous nerve
- 87. Medial antebrachial cutaneous nerve
- 88. Median nerve
- 89. Common palmar digital nerves
- 90. Proper palmar digital nerves
- 91. Ulnar nerve
- 92. Ramus dorsalis
- 93. Palmar branch of ulnar nerve
- 94. Superficial branch
- 95. Deep branch
- 96. Dorsal digital nerves
- 97. Common palmar digital nerves
- 98. Proper palmar digital nerves
- 99. Radial nerve
- 100. Posterior brachial cutaneous nerve
- 101. Posterior antebrachial cutaneous nerve
- 102. Posterior interosseous nerve
- 103. Dorsal digital nerves

NERVI SPINALES

- 63. Radix ventralis
- 64. Radix dorsalis
- 65. Ganglion spinale
- 66. Ramus ventralis
- 67. Ramus dorsalis

NERVI CERVICALES

- 68. N.suboccipitalis
- 69. N.occipitalis major
- 70. N.occipitalis minor
- 71. Nn.supraclaviculares
- 72. N.phrenicus

PLEXUS BRACHIALIS

- 73. N.dorsalis scapulae
- 74. N.thoracicus longus
- 75. Nn.thoracici ventrales
- 76. N.subclavius
- 77. N.suprascapularis
- 78. Nn.subscapulares
- 79. N.axillaris
- 80. N.cutaneus brachii lateralis superior
- 81. Fasciculus lateralis
- 82. Fasciculus medialis
- 83. Fasciculus posterior
- 84. N.musculocutaneus
- 85. N.cutaneus antebrachii lateralis
- 86. N.cutaneus brachii medialis
- 87. N.cutaneus antebrachii medialis
- 88. N.medianus
- 89. Nn.digitales palmares communes
- 90. Nn.digitales palmares proprii
- 91. N.ulnaris
- 92. Ramus dorsalis n.ulnaris
- 93. Ramus palmaris n.ulnaris
- 94. Ramus superficialis
- 95. Ramus profundus
- 96. Nn.digitales dorsales
- 97. Nn.digitales palmares communes
- 98. Nn.digitales palmares proprii
- 99. N.radialis
- 100. N.cutaneus brachii posterior
- 101. N.cutaneus antebrachii posterior
- 102. N.interosseus
- 103. Nn.digitales dorsales

脊髓神經

- 63. 前根
- 64. 後根
- 65. 脊髓神經節
- 66. 前枝
- 67. 後枝

頸神經

- 68. 後頭下神經
- 69. 大後頭神經
- 70. 小後頭神經
- 71. 鎖骨上神經
- 72. 橫隔神經

腕神經叢

- 73. 肩甲背神經
- 74. 長胸神經
- 75. 前胸神經
- 76. 鎖骨下筋神經
- 77. 肩甲上神經
- 78. 肩甲下神經
- 79. 腋窩神經
- 80. 上外側上腕皮神經
- 81. 外側神經束
- 82. 內側神經束
- 83. 後神經束
- 84. 筋皮神經
- 85. 外側前腕皮神經
- 86. 內側上腕皮神經
- 87. 內側前腕皮神經
- 88. 正中神經
- 89. 總掌側指神經
- 90. 固有掌側指神經
- 91. 尺骨神經
- 92. 手背枝
- 93. 掌枝
- 94. 淺枝
- 95. 深枝
- 96. 背側指神經
- 97. 總掌側指神經
- 98. 固有掌側指神經
- 99. 橈骨神經
- 100. 後上腕皮神經
- 101. 後前腕皮神經
- 102. 後(前腕)骨間神經
- 103. 背側指神經

Thoracic nerves

- 104. Posterior ramus
- 105. Anterior ramus

LUMBAR NERVES

- 106. Posterior ramus
- 107. Anterior ramus
- 108. Lumbar plexus
- 109. Iliohypogastric nerve
- 110. Ilioinguinal nerve
- 111. Anterior scrotal nerves
- 112. Genitocrural nerve
- 113. Femoral branch
- 114. Genital branch
- 115. Lateral cutaneous nerve
- 116. Obturator nerve
- 117. Femoral nerve
- 118. Anterior cutaneous branches
- 119. Infrapatellar branch
- 120. Saphenous nerve
- 121. Sacral plexus
- 122. Superior gluteal nerve
- 123. Inferior gluteal nerve
- 124. Posterior cutaneous nerve
- 125. Sciatic nerve
- 126. Common fibular nerve
- 127. Lateral cutaneous nerve
- 128. Superficial fibular nerve
- 129. Dorsal medial cutaneous nerve
- 130. Intermediate dorsal cutaneous nerve
- 131. Dorsal digital nerves of superficial fibular nerve
- 132. Deep fibular nerve
- 133. Tibial nerve
- 134. Medial cutaneous nerve
- 135. Dorsal lateral cutaneous nerve
- 136. Medial plantar nerve
- 137. Common plantar digital nerves
- 138. Proper plantar digital nerves
- 139. Lateral plantar nerve
- 140. Common plantar digital nerves
- 141. Pudendal plexus
- 142. Pudendal nerve
- 143. Inferior rectal nerves
- 144. Posterior scrotal nerves
- 145. Dorsal nerve of penis

NERVI THORACICI

- 104. Rami dorsales
- 105. Rami ventrales

NERVI LUMBALES

- 106. Rami dorsales
- 107. Rami ventrales
- 108. Plexus lumbalis
- 109. N.iliohypogastricus
- 110. N.ilioinguinalis
- 111. Nn.scrotales anteriores
- 112. N.genitofemoralis
- 113. Ramus femoralis
- 114. Ramus genitalis
- 115. N.cutaneus femoris lateralis
- 116. N.obturatorius
- 117. N.femoralis
- 118. Rami cutanei
- 119. Ramus infrapatellaris
- 120. N.saphenus
- 121. Plexus sacralis
- 122. N.gluteus superior
- 123. N.gluteus inferior
- 124. N.cutaneus femoris posterior
- 125. N.ischiadicus
- 126. N.fibularis communis
- 127. N.cutaneus surae lateralis
- 128. N.fibularis superficlis
- 129. N.cutaneus dorsalis medialis
- 130. N.cutaneus dorsalis intermedius
- 131. Nn.digitales dorsales pedis
- 132. N.fibularis profundus
- 133. N.tibialis
- 134. N.cutaneus surae medialis
- 135. N.cutaneus dorsalis lateralis
- 136. N.plantarum medialis
- 137. Nn.digitales plantares communes
- 138. Nn.digitales plantares proprii
- 139. N.plantarum lateralis
- 140. Nn.digitales plantares communes
- 141. Plexus pudendus
- 142. N.pudendus
- 143. Nn.rectales inferiores
- 144. Nn.scrotales posteriores
- 145. N.dorsalis penis

胸神經

- 104. 後枝
- 105. 前枝 (肋間神經)

腰神經

- 106. 後枝
- 107. 前枝
- 108. 腰神經叢
- 109. 腸骨下腹神經
- 110. 腸骨鼠徑神經
- 111. 前陰囊神經
- 112. 陰部大腿神經
- 113. 大腿枝
- 114. 陰部枝
- 115. 外側大腿皮神經
- 116. 閉鎖神經
- 117. 大腿神經
- 118. 前皮枝
- 119. 膝蓋下枝
- 120. 伏在神經
- 121. 仙骨神經叢
- 122. 上殿神經
- 123. 下殿神經
- 124. 後大腿皮神經
- 125. 坐骨神經
- 126. 總腓骨神經
- 127. 外側腓腹皮神經
- 128. 淺腓骨神經
- 129. 內側足背皮神經
- 130. 中間足背皮神經
- 131. 足背指神經
- 132. 深腓骨神經
- 133. 頸骨神經
- 134. 內側腓腹皮神經
- 135. 外側足背皮神經
- 136. 內側足底神經
- 137. 總底側指神經
- 138. 固有底側指神經
- 139. 外側足底神經
- 140. 總底側指神經
- 141. 陰部神經叢
- 142. 陰部神經
- 143. 下直腸神經
- 144. 後陰囊神經
- 145. 陰莖背神經

SYMPATHETIC NERVOUS SYSTEM

- 146. Sympathetic trunk
- 147. Middle cervical ganglion
- 148. Inferior cervical ganglion
- 149. Thoracic ganglia
- 150. Greater splanchnic nerve
- 151. Lesser splanchnic nerve
- 152. Communicating branch
- 153. Lumbar ganglia
- 154. Sacral ganglia
- 155. Coccygeal plexus

BONES OF CRANIUM

- 156. Occipital bone
- 157. Greater wing
- 158. Sphenoidal sinus
- 159. Temporal bone
- 160. Mastoid process
- 161. Styloid process
- 162. External acoustic pore
- 163. Squamous par
- 164. Zygomatic process(cut)
- 165. Parietal bone
- 166. Frontal bone
- 167. Zygomatic process
- 168. Nasal part
- 169. Frontal sinus
- 170. Nasal bone
- 171. Upper jaw bone
- 172. Frontal process
- 173. Zygomatic process
- 174. Mandible
- 175. Angle of mandible
- 176. Condylar process
- 177. Hyoid bone

VERTEBRAL COLUMN

- 178. Cervical vertebrae[C1-C7]
- 179. Thoracic vertebrae[T1-T12]
- 180. Lumbar vertebrae[L1-L5]
- 181. Vertebrae thoracicae[T1-T12]
- 182. Coccygeal vertebrae[Co1-Co4]
- 183. Anterior longitudinal ligament
- 184. Intervertebral disk
- 185. Hip bone

SYSTEMA NERVORUM SYMPATHICUS

- 146. Truncus sympathicus
- 147. Ganglion cervicale medium
- 148. Ganglion cervicale caudale
- 149. Ganglion thoracica
- 150. N.splanchnicus major
- 151. N.splanchnicus minor
- 152. Rami communicantes
- 153. Ganglia lumbalia
- 154. Ganglia sacralia
- 155. Plexus coccygeus

OSSA CRANII

- 156. Os occipitale
- 157. Ala major
- 158. Sinus sphenoidalis
- 159. Os temporale
- 160. Processus mastoideus
- 161. Processus styloideus
- 162. Porus acusticus externus
- 163. Pars squamosa
- 164. Processus zygomaticus(cut)
- 165. Os parietale
- 166. Os frontale
- 167. Processus zygomaticus
- 168. Pars nasalis
- 169. Sinus frontalis
- 170. Os nasale
- 171. Maxilla
- 172. Processus frontalis
- 173. Processus zygomaticus
- 174. Mandibula
- 175. Angulus mandibulae
- 176. Processus condylaris
- 177. Os hyoideum

COLUMNA VERTEBRALIS

- 178. Vertebrae cervicales I-VII
- 179. Vertebrae thoracicae I-XII
- 180. Vertebrae lumbales I-V
- 181. Vertebrae sacralis I-V
- 182. Vertebrae coccygea I-IV
- 183. Lig.longitudinale anterius
- 184. Discus intervertebralis
- 185. Os coxae

交感神經系

- 146. 交感神經幹
- 147. 中頸神經節
- 148. 下頸神經節
- 149. 胸神經節
- 150. 大內臟神經
- 151. 小內臟神經
- 152. 交通枝
- 153. 腰神經節
- 154. 仙骨神經節
- 155. 尾骨神經叢

頭蓋骨

- 156. 後頭骨
- 157. 大翼 (蝶形骨)
- 158. 蝶形骨洞
- 159. 側頭骨
- 160. 乳樣突起
- 161. 莖狀突起
- 162. 外耳孔
- 163. 鱗部
- 164. 頰骨突起 (斷)
- 165. 頭頂骨
- 166. 前頭骨
- 167. 頰骨突起
- 168. 鼻部 (眉間)
- 169. 前頭洞
- 170. 鼻骨
- 171. 前顎骨
- 172. 前頭突起
- 173. 頰骨突起
- 174. 下顎骨
- 175. 下顎角
- 176. 關節突起
- 177. 舌骨

脊柱

- 178. 第一~第七頸椎
- 179. 第一~第十二胸椎
- 180. 第一~第五腰椎
- 181. 第一~第五仙椎
- 182. 第一~第四尾椎
- 183. 前縱韌帶
- 184. 椎間凹板
- 185. 寬骨

- 186. Iliac bone
- 187. Pubic bone
- 188. Ischial bone
- 189. Inguinal ligament
- 190. Pubic symphysis

**FACE AND CERVICAL REGION
(MEDIAN PLANE)**

- 191. Perpendicular plate
- 192. Vomer
- 193. Septal nasal cartilage
- 194. Pharyngeal opening of
pharyngotympanic (auditory) tube
- 195. Nasopharyngeal cavity
- 196. Cavity of pharynx
- 197. Uvula
- 198. Palatine tonsil
- 199. Vestibule of larynx
- 200. Epiglottic cartilage
- 201. Thyroid cartilage
- 202. Cricoid cartilage
- 203. Vocal ligament
- 204. Windpipe
- 205. Right main bronchus
- 206. Left main bronchus
- 207. Esophagus

ARTERY

- 208. Ascending aorta
- 209. Aortic arch
- 210. Descending aorta
- 211. Drachiocephalic (arterial) trunk
- 212. Right common carotid artery
- 213. Right subclavian artery
- 214. Left common carotid artery
- 215. Left subclavian artery

Stomach

- 216. Cardia
- 217. Pylorus
- 218. Lesser curvature
- 219. Greater curvature
- 220. Fundus of stomach
- 221. Duodenum
- 222. Pancreas

- 186. Os ilium
- 187. Os pubis
- 188. Os ischii
- 189. Lig.inguinale
- 190. Symphysis pubica

**FACIES ET REGIO COLLI
(MEDIANUS cut)**

- 191. Lamina perpendicularis
- 192. Vomer
- 193. Cartilago septi nasi
- 194. Ostium pharyngeum tubae
- 195. Cavum pharyngonasalis
- 196. Cavum pharyngis
- 197. Uvula
- 198. Tonsilla palatina
- 199. Vestibulum laryngis
- 200. Cartilago epiglottica
- 201. Cartilago thyr(e)oidea
- 202. Cartilago cricoidea
- 203. Lig.vocale
- 204. Trachea
- 205. Bronchus principalis dexter
- 206. Bronchus principalis sinister
- 207. Esophagus

ARTERIAE

- 208. Aorta ascendens
- 209. Arcus aortae
- 210. Aorta descendens
- 211. Truncus brachiocephalicus
- 212. A.carotis communis dextra
- 213. A.subclavia dextra
- 214. A.carotis communis sinistra
- 215. A.subclavia sinistra

VENTRICULUS

- 216. Cardia
- 217. Pylorus
- 218. Curvatura ventriculi minor
- 219. Curvatura ventriculi major
- 220. Fundus ventriculi
- 221. Duodenum
- 222. Pancreas

- 186. 腸骨
- 187. 恥骨
- 188. 坐骨
- 189. 鼠径靱帯
- 190. 恥骨結合

顔及頸部の正中断面

- 191. 鉛直板 (篩骨の)
- 192. 鋤骨
- 193. 鼻中隔軟骨
- 194. 耳管咽頭口
- 195. 鼻咽頭腔
- 196. 咽頭腔
- 197. 口蓋垂
- 198. 口蓋扁桃
- 199. 喉頭前庭
- 200. 喉頭蓋軟骨
- 201. 甲状軟骨
- 202. 輪状軟骨
- 203. 声帯靱帯
- 204. 気管
- 205. 右気管支
- 206. 左気管支
- 207. 食道

動脈

- 208. 上行大動脈
- 209. 大動脈弓頭
- 210. 下行大動脈
- 211. 腕頭動脈
- 212. 右総頸動脈
- 213. 右鎖骨下動脈
- 214. 左総頸動脈
- 215. 左鎖骨下動脈

胃

- 216. 噴門
- 217. 幽門
- 218. 小彎
- 219. 大彎
- 220. 胃底
- 221. 十二指腸
- 222. 膵臓

 **KYOTO KAGAKU co.,LTD**

■ **Main Office and Factory**

15 Kitanechoya-cho Fushimi-ku Kyoto 612-8388, Japan
Telephone : 81-75-605-2510 Facsimile : 81-75-605-2519

■ **LA Office (for USA , CANADA and Mexico customers)**

3109 Lomita Boulevard, Torrance, CA 90505 ,USA
Telephone : 1-310-325-8860 Facsimile : 1-310-325-8867

 株式
会社 **京都科学**

■ **本社・工場**

〒612-8388 京都市伏見区北寝小屋町15番地
TEL : 075-605-2510 (直通) FAX : 075-605-2519

■ **東京支店**

〒113-0033 東京都文京区本郷三丁目26番6号
NREG本郷三丁目ビル2階
TEL : 03-3817-8071 (直通) FAX : 03-3817-8075

URL ● <http://www.kyotokagaku.com> e-mail ● rw-kyoto@kyotokagaku.co.jp